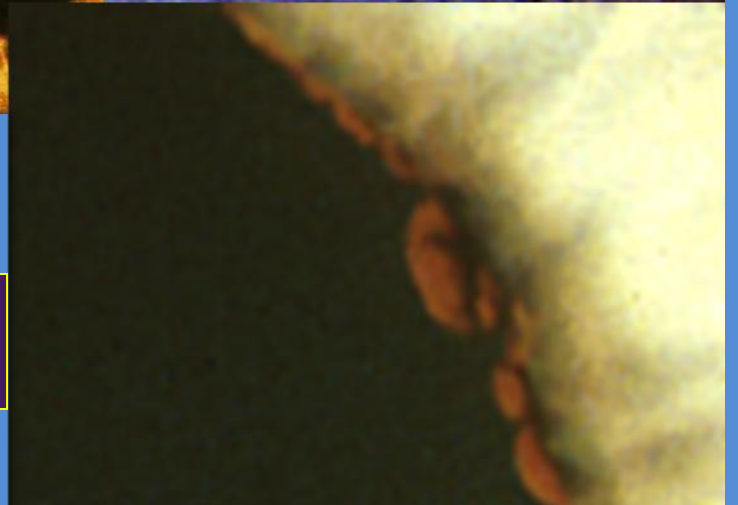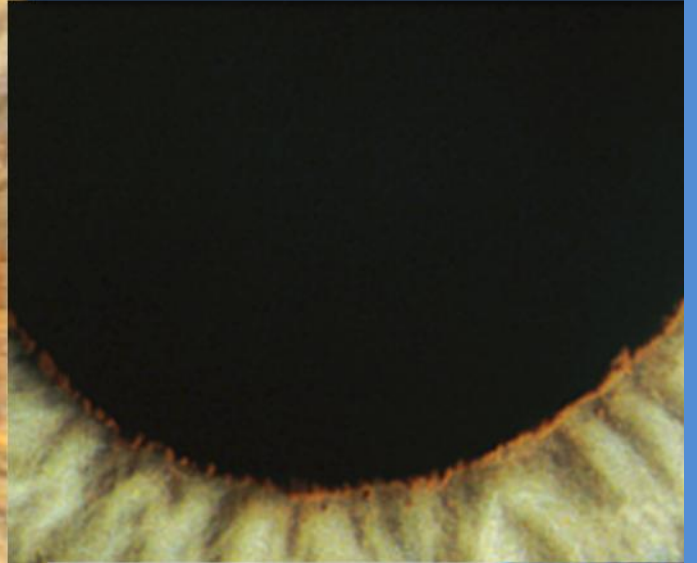

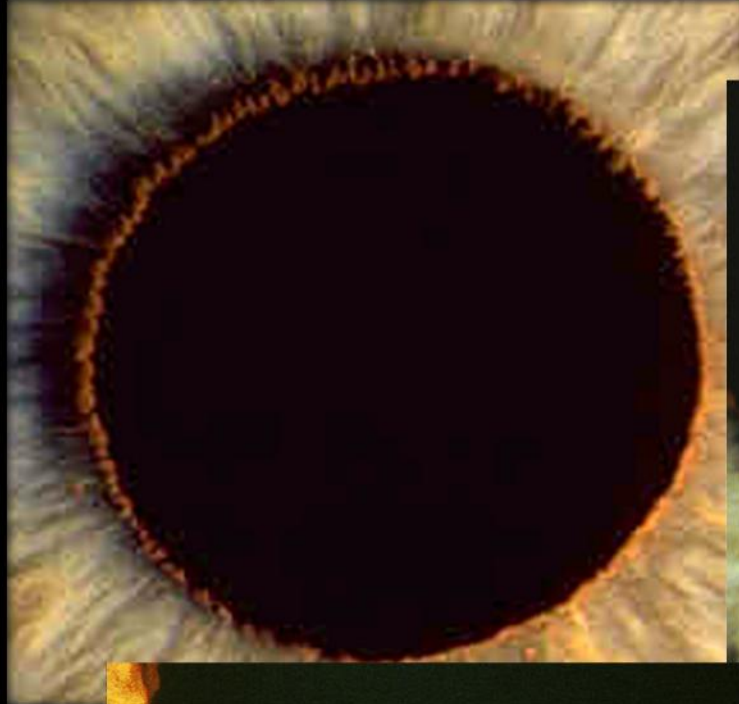
INNER PUPILLARY BORDER



Dr. Daniele Lo Rito